

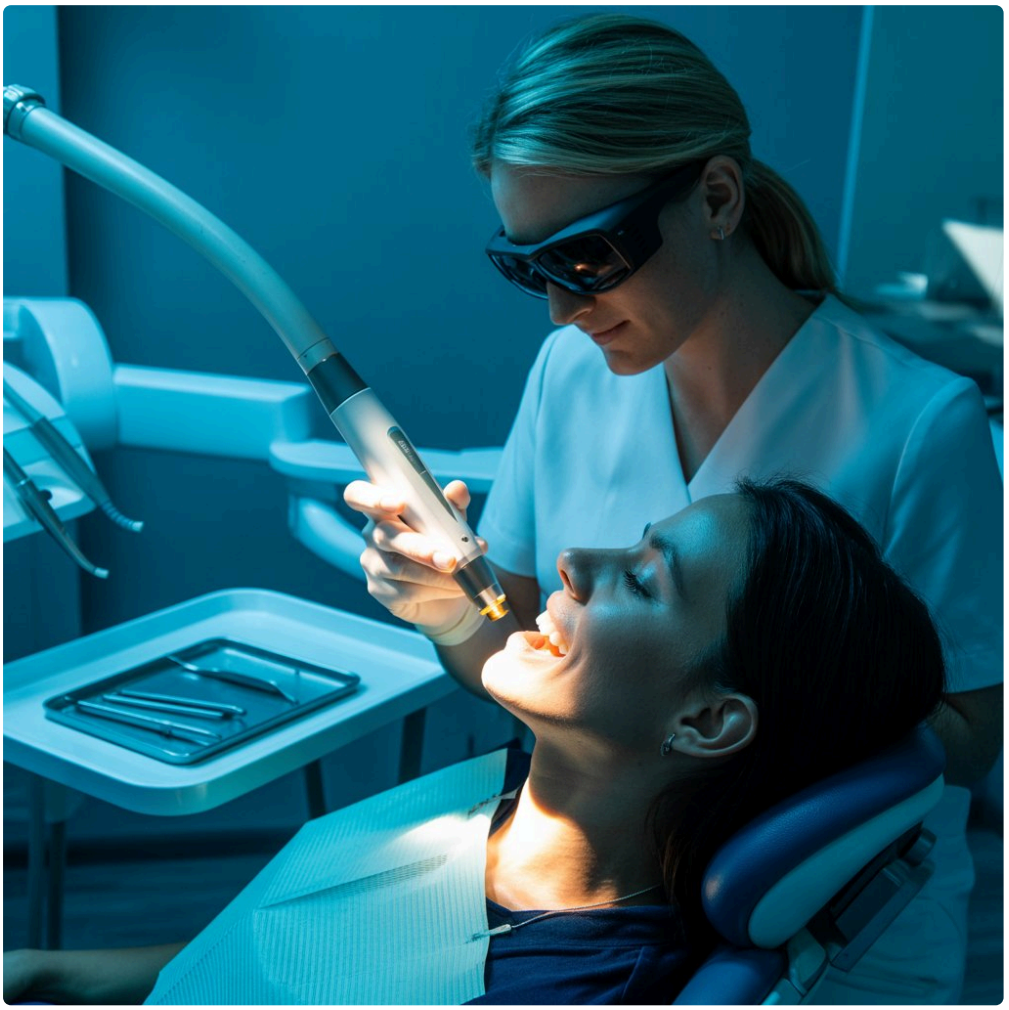

A true dental emergency rarely arrives at a convenient hour. It shows up during dinner, in the middle of a school day, on a weekend road trip, or a few hours after a routine filling seemed perfectly fine. The common thread is urgency. Pain escalates fast in the mouth, swelling can spread, and injuries that look minor at first can become much harder to repair if treatment is delayed. That is why an Emergency Dentist sees a surprisingly consistent pattern of problems every day, even though each patient arrives with a different story.

What makes dental emergencies distinct from ordinary dental complaints is not just discomfort. It is the combination of pain, infection risk, bleeding, trauma, and lost function. A cracked molar can suddenly make chewing impossible. An abscess can turn a nagging toothache into facial swelling overnight. A knocked-out front tooth becomes a race against time measured in minutes, not days. The work of emergency care is part diagnosis, part pain control, and part damage limitation, with a steady emphasis on preserving as much healthy tooth and surrounding tissue as possible.

People often assume emergency dentistry is mostly about severe toothaches. Those are certainly common, but the day-to-day reality is broader. Emergency visits often involve broken restorations, sports injuries, sudden swelling, gum infections, cracked cusps, dry sockets, and children who Emergency Dentist fell face-first onto the living room floor. There is also a fair amount of detective work. The pain a patient feels in one tooth may actually be referred from another. A cracked tooth may not show up clearly on the first X-ray. A swelling under the jaw can point to a more serious infection than the patient realized when they booked the appointment.

The toothache that could not wait

Severe tooth pain is one of the most common reasons patients seek same-day care. Sometimes the cause is obvious, such as a large cavity that has reached the nerve. Other times the pain began after months of mild sensitivity that the patient worked around by chewing on the other side. Then one day the tooth crosses a threshold. Cold drinks sting, biting sends a sharp bolt through the jaw, and the ache lingers long after the trigger is gone.

From a clinical standpoint, not all toothaches are equal. One pattern suggests inflamed nerve tissue that may still be recoverable, while another points to an infected or dying pulp that will likely need root canal treatment or extraction. The distinction matters because it changes both the urgency and the treatment options. A patient who says, “It hurts only when I drink ice water, then settles quickly,” may be in a very different situation from someone who says, “It woke me up at 2 a.m. And now my whole face throbs.”

An Emergency Dentist will typically examine the tooth, test temperature response, check the bite, and take targeted radiographs. That process sounds routine, but it is often where the most important judgment happens. A deep cavity near the nerve, a cracked cusp, a hidden abscess, or an old filling leaking bacteria around the margin can all create similar symptoms. Treating the pain properly means treating the right problem, not simply prescribing medication and hoping the inflammation settles down.

In practice, many of these visits end with one of several paths. The tooth may need emergency root canal access to relieve pressure. It may need extraction because the decay or fracture is too extensive to restore predictably. Sometimes the immediate goal is more modest, such as adjusting the bite, placing a sedative dressing, or starting antibiotics when swelling indicates active infection. Definitive treatment may come later, but the first appointment is about stopping the situation from getting worse.

Swelling and dental abscesses

Facial swelling changes the tone of an emergency visit immediately. A localized gum boil above a tooth can be painful but manageable. Diffuse swelling that pushes into the cheek, under the eye, or beneath the jaw raises a

different level of concern. Dental infections can spread through tissue spaces, and while most remain localized, some become medically serious.

This is one of those situations where timing matters more than people expect. Patients often wait because the pain temporarily decreased, assuming the tooth improved. In reality, when pressure inside the tooth drops because the nerve has died, pain can lessen right before the infection spreads into surrounding bone and soft tissue. By the time facial swelling appears, the issue has usually moved beyond “watch it for a day.”

An Emergency Dentist looks for several warning signs. Fever, difficulty swallowing, trouble opening the mouth, voice changes, and swelling under the tongue or jaw are all red flags. Those findings can shift care toward urgent medical evaluation, not just dental treatment. In less severe cases, treatment may involve draining the abscess, opening the tooth for root canal treatment, extracting the source tooth, and using antibiotics when indicated. Antibiotics alone are rarely the full answer. If the source of infection remains trapped, symptoms often return.

Patients are often surprised that two abscesses can look similar and behave very differently. One can be drained chairside with immediate relief. Another may require referral because the swelling tracks into deeper spaces or because the patient’s medical history, such as diabetes or immunosuppression, increases the risk. Experience matters here. The decision is not simply whether the tooth is infected. It is whether the infection can be controlled safely in a dental setting that day.

Broken, cracked, and fractured teeth

Teeth do not always fail dramatically. Very often, a patient arrives saying they bit down on bread with seeds, a chicken bone, or a hard candy and “something just gave way.” The filling that had been in place for fifteen years broke loose, taking part of the tooth with it. Or a molar that had a root canal years earlier suddenly sheared at the *Emergency Dentist* gumline because it no longer had enough tooth structure to support daily chewing forces.

Cracks are among the more frustrating emergencies because they are not always easy to see. A tooth can look mostly intact and still cause severe pain on biting release. That classic symptom often points to a crack traveling through the cusp or into the body of the tooth. The challenge is determining whether the fracture is superficial and repairable, or whether it extends below the gumline or into the root, where the prognosis worsens.

When the damage is limited, emergency treatment may include smoothing sharp edges, placing a bonded restoration, fitting a temporary crown, or protecting the tooth until definitive treatment can be completed. If the fracture exposes the nerve, root canal treatment may be necessary before the tooth can be rebuilt. If the crack runs vertically down the root, extraction is often the only realistic option.

Front teeth create a different problem. Even a small chip can feel like an emergency because it changes appearance immediately. For a patient with a visible smile line, the emotional impact can be as significant as the physical one. A skilled emergency repair on an incisor often requires both structural judgment and aesthetic restraint. Rebuilding the edge too bulky looks unnatural. Leaving it rough risks cutting the lip or tongue. Good emergency care balances form, function, and what can be achieved reliably in a single visit.

Knocked-out teeth and other traumatic injuries

Trauma cases tend to move quickly because treatment windows are short. A completely knocked-out permanent tooth, called an avulsed tooth, is the clearest example. If it is replanted promptly, sometimes within 30 to 60 minutes for the best odds, the chances of saving it improve considerably. If it dries out for too long, the ligament cells on the root surface begin to die, and long-term success drops.

The first aid advice for an avulsed permanent tooth is straightforward enough to remember under stress:

1. Pick the tooth up by the crown, not the root.
2. If it is dirty, rinse it gently with milk or saline, or briefly with water.
3. Place it back in the socket if possible, or store it in milk.
4. Get to an Emergency Dentist immediately.
5. Do not replant a baby tooth.

That sequence has saved many teeth. It is also one of the few true dental emergencies where what happens before the patient reaches the office may matter as much as what happens in the chair.

Not every trauma case involves a tooth on the floor. Some teeth are pushed inward, shifted sideways, loosened, or fractured at the root. Lips and gums may be lacerated, and bits of tooth sometimes embed in soft tissue. Children often present after bicycle falls or sports injuries with a mix of bleeding, swelling, and frightened parents trying to reconstruct what happened. Adults appear after collisions, work accidents, or simple household falls. The treatment plan depends on age, root development, direction of displacement, and whether the tooth involved is primary or permanent.

One practical point matters here. A tooth that looks “only a little loose” after trauma still needs evaluation. Damage to the supporting bone or root may not be obvious without imaging and follow-up. Emergency care is not just about what can be fixed on day one. It is about setting the tooth up for the best long-term survival.

Lost fillings, crowns, and bridges

This category sounds minor until you see how often it disrupts eating, speaking, and sleep. A lost crown can expose a heavily prepared tooth that becomes extremely sensitive to air and temperature. A lost filling can leave a sharp crater that packs food and irritates the tongue. A bridge that comes loose may still be hanging on one side, shifting every time the patient talks.

The urgency depends on what is underneath. If the tooth is structurally strong and merely uncovered, a recementation or temporary protection may be enough until the definitive appointment. If the crown came off because the tooth decayed underneath or fractured, the emergency visit becomes more complex. The dentist may need to remove decay, rebuild the core, evaluate whether the tooth can still support a restoration, and decide whether gum tissue, root structure, or remaining walls make salvage realistic.

There is also a difference between what can be done quickly and what should be done carefully. Recementing a crown back onto a decayed or cracked tooth without assessing the cause can buy a patient a few days, but it may also mask a more serious problem. Good emergency treatment does not just put the piece back where it came from. It checks why it failed.

Patients sometimes try over-the-counter temporary cements, which can be helpful for short-term comfort when used correctly, but they are not a substitute for examination. A crown that no longer fits passively may indicate tooth movement, decay, or fracture. Forcing it into place can complicate the eventual repair.

Gum and periodontal emergencies

Not all urgent dental visits begin with the tooth itself. Gum problems can create pain that feels every bit as severe. One common example is a periodontal abscess, where infection builds in a deep gum pocket beside the tooth. The patient often describes a throbbing, swollen area that hurts to bite on, sometimes with a bad taste as drainage comes and goes. Unlike a root-tip abscess, the tooth may still respond normally to vitality tests, which is why careful diagnosis matters.

Another painful condition is pericoronitis, an infection around a partially erupted wisdom tooth. Food debris and bacteria collect under the gum flap, and the tissue becomes swollen, tender, and difficult to clean. Some patients can barely close their teeth together because the opposing tooth bites into the inflamed gum. Others notice swollen glands, bad breath, or a limited ability to open their mouth. Initial care often involves irrigation, cleaning, pain control, and in some cases antibiotics, followed by a discussion about whether the wisdom tooth should be removed once the acute flare settles.

There are also visits for spontaneous gum bleeding, ulcerated tissue, or food and foreign objects wedged under the gums. Popcorn husks, meat fibers, and small seed fragments cause more trouble than most people expect. A patient may present convinced they have a broken tooth when the real issue is a sliver lodged beneath the gumline, creating sharp, localized pain. The relief after removal can be immediate.

Dry socket after extraction

Few post-operative problems are as miserable, or as misunderstood, as dry socket. This usually develops a few days after a tooth extraction, especially lower wisdom teeth. Instead of improving steadily, the patient experiences worsening pain that can radiate to the ear, temple, or neck. The socket looks empty or has exposed bone where the blood clot should have been.

Dry socket is not a typical infection, and antibiotics are not the main treatment. The problem is loss of the protective clot and exposure of sensitive bone and nerve endings. An Emergency Dentist usually focuses on gentle irrigation, medicated dressing when appropriate, and pain relief while the socket heals. Patients often fear something has gone terribly wrong with the extraction itself. In reality, dry socket is an unpleasant but well-recognized complication, with risk influenced by factors such as smoking, difficult extractions, and sometimes oral contraceptive use.

This is a good example of why emergency dental care often involves reassurance alongside treatment. When pain is severe and appears days after a procedure, patients understandably worry that the area is infected or permanently damaged. Clear explanation helps, especially when paired with a treatment plan that makes them more comfortable within the same visit.

Broken dentures and orthodontic emergencies

Not every emergency involves natural teeth. Dentures crack, clasps snap, and partials suddenly rub raw spots into already thin gum tissue. For an older adult who relies on a lower denture for speech and a partial denture for eating, a fracture can disrupt far more than convenience. Nutrition, social confidence, and comfort all take a hit.

Orthodontic issues also drive urgent visits, particularly among teenagers. A loose bracket may not be a true emergency, but a protruding wire that slices into the cheek certainly feels like one. Retainers swallowed by pets, aligners that no longer seat after trauma, or orthodontic appliances impinging into soft tissue can all require same-day management. In many of these cases, the immediate goal is simple, remove the source of irritation, stabilize the appliance if possible, and prevent soft tissue injury until the patient returns to the treating orthodontist.

These visits highlight an important reality. Emergency dentistry is not always dramatic. Sometimes it is the skilled management of very practical problems that have become unbearable in the context of daily life.

When pain is not actually coming from a tooth

One of the more challenging parts of emergency care is knowing when the mouth is not the whole story. Sinus inflammation can mimic upper molar pain. Jaw muscle spasm can create diffuse aching and bite tenderness. Neuralgic pain can feel electric and severe without any visible dental cause. Even heart-related pain, though less common, can sometimes refer to the jaw.

This is where clinical restraint matters. Not every painful tooth should be drilled, and not every radiographic shadow explains the patient's symptoms. A good Emergency Dentist knows when findings do not line up neatly and when another path, medical referral, further testing, or short-interval review is the wiser choice. Experience teaches caution. Once a tooth is extracted, there is no undoing the decision.

What deserves immediate attention

Patients often ask whether they truly need emergency care or whether the issue can wait. A few situations nearly always justify prompt evaluation:

- uncontrolled bleeding in the mouth
- facial swelling, especially with fever or difficulty swallowing
- a knocked-out permanent tooth
- severe pain that prevents sleep or eating
- trauma with broken, displaced, or loose teeth

Many other problems still deserve timely care, even if they are not life-threatening that hour. A lost crown on a front tooth before a major event may be urgent for obvious reasons. A cracked molar with only occasional pain may seem less dramatic, but leaving it alone can allow the crack to deepen until the tooth becomes unrestorable.

Why quick treatment often saves more than comfort

There is a tendency to think of emergency treatment as a temporary patch. Sometimes it is, but timely intervention often changes the final outcome. A tooth seen early after fracture may be crownable. The same tooth seen two weeks later, after repeated splitting under function, may need extraction. An abscess drained promptly may resolve without the infection spreading. A knocked-out tooth stored correctly and replanted quickly may remain functional for years.

The practical value is not just biological. Early care can save money, reduce time away from work, and avoid more invasive procedures. It is far less complicated to repair a lost filling than to rebuild a tooth that has since cracked into the pulp. It is easier to address pericoronitis before the swelling becomes severe enough to limit mouth opening and make treatment more difficult.

Emergency dentistry, at its best, is decisive without being reckless. It prioritizes pain relief and safety, but it also looks one step ahead. The immediate issue has to be managed, yet every choice should preserve future options where possible. That might mean stabilizing a cracked tooth for a specialist rather than rushing to remove it. It might mean extracting a hopeless tooth the same day because delay adds risk without benefit. The judgment lies in knowing the difference.

For patients, the key takeaway is simple. Sudden dental pain, swelling, trauma, or a broken tooth rarely improves through wishful thinking. An Emergency Dentist treats these problems every day because they are common, disruptive, and often time-sensitive. The sooner the cause is identified, the better the chance of protecting both comfort and long-term oral health.

Vitality Dental
1220 Coit Rd # 106, Plano, TX 75075, United States
+1 972-645-4100

FAQ About Emergency Dentist

What counts as a dental emergency?

A knocked-out tooth, significant mouth injury, severe tooth pain, or painful swelling warrants prompt evaluation. Call your dentist and describe your symptoms so the office can advise you on how urgently you need care.

What should I do if I knock out a permanent tooth?

Call a dentist immediately. Handle the tooth by the crown, avoid touching the root, and keep it moist. If you cannot put it back into the socket easily, transport it in milk or a tooth-preservation solution. Bring it with you to the appointment.

Should I go to the emergency room for a dental emergency?

Seek emergency medical care right away if you have trouble breathing or swallowing, uncontrolled bleeding, or a serious facial injury. For an isolated tooth injury or toothache without those symptoms, call a dentist promptly for guidance.